

Operated unstable petrochanteric fractures leading to osteonecrosis of femoral headNeetin P. Mahajan¹, Ankit A. Marfatia², Nadir Z. Shah³, F Memon³, S. Mukherjee², N. Jagani²³Associate professor and H.O.D, Department of Orthopaedics, Sir J. J. Group of Hospital & Grant Medical College, Mumbai, India²Senior registrar, Department of Orthopaedics, Sir J. J. Group of Hospital & Grant Medical College, Mumbai, India³Assistant professor, Department of Orthopaedics, Sir J. J. Group of Hospital & Grant Medical College, Mumbai, India**ABSTRACT**

Petrochanteric femur fractures have been one of the most frequently operated fracture types and have been associated with medical complications such as cardiac and pulmonary complications. Nonunion and malunions have also been reported with implant insitu. Implant malfunction have been reported due to a combination of implant fatigue, shaft fixation failure with broken screws, femoral head medial penetration, screw cutout and disassembly of the device components. We present a case of 25 year old Indian male with Osteonecrosis of the Femoral head with a past history of petrochanteric fracture operated with a dynamic condylar screw and no other co-morbidities.

Keywords: Petrochanteric femur fracture, Osteonecrosis, Avascular Necrosis, Dynamic condylar screw.

Introduction

Petrochanteric femur fracture has been the most frequently operated fracture types. There have been many classification systems for the same. The AO classification system for petrochanteric fractures is used both for diagnosis as well as suggest the treatment modality. Petrochanteric fractures for which sliding hip screw, dynamic condylar screw; cephalomedullary nails can be considered the standard for surgery. The construct strength is based on fracture geometry bone quality as well surgeon controlled such as quality of reduction, implant placement and implant selection. The known complications for the petrochanteric fractures have been medical complication, nonunions, malunions; implant malfunction. Osteonecrosis of the femoral head is a progressive disease that generally affects patients in the 3rd through 5th decade of their life. The avascular state of the bone is a result of loss of circulation from numerous possible causes. We present a case of Osteonecrosis of the Femoral Head secondary to AO 31.A3.1 petrochanteric fracture operated with a 95 Dynamic Condylar Screw.

***Correspondence**

Dr. Nadir Z. Shah Assistant professor, Department of Orthopaedics, Sir J. J. Group of Hospital & Grant Medical College, Mumbai, India.

E Mail: drgrehgde@gmail.com

Case Report

A 25 year old Indian male patient with a history of pain in the left hip since the past 2 years presented to us in our outpatient department of orthopaedics at Sir J. J. Group of Hospital & Grant Medical College. He had a history of Road traffic accident about 5 years ago and was diagnosed with a right petrochanteric femur fracture for which he was admitted at a tertiary health care centre, there were no other injuries documented. He was operated with a 95 Degree Dynamic Condylar Screw 7 days after the trauma and was discharged after a few days with the hospital stay and post-operative period being uneventful. Mobilization was started after the first check dress and ambulation was started after about 4 weeks. He kept regular follow-ups with the tertiary health care centre and was advised implant removal after 1 year of the primary surgery. The implant removal surgery was uneventful as stated in the documentation of the same. The patient was asymptomatic for 2 years and was able to do all the activities of daily living pain free. He developed insidious pain in the right hip which was dull aching, localized pain which increased on walking long distance and was relieved at rest. There was no history of any diurnal variation, no waxing or waning of symptoms, no history of any other trauma, no history of fever, no history of steroid, tobacco consumption or

alcohol consumption. The pain increased in intensity and for the same he started pain medications which relieved the symptoms partially. He presented to us with pain on terminal motion of the right hip which affected his activities of daily living. On examination he had a surgical scar over the lateral aspect of the hip with tenderness over the right hip, the Range of motion of the right hip were only terminally restricted with sectoral sign being positive. He was investigated in the

form of standard radiographs and MRI which showed Grade 3 AVN. All other blood investigation was within normal limit. He was started on alendronate 70mg once a week and analgesics for the pain as the patient was unwilling for any surgical intervention and on the last follow up the patient was not on any analgesics and continuing the use of alendronate, the patient was pain free.

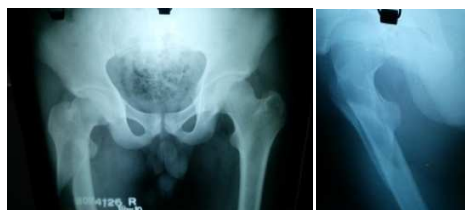

Fig 1: Radiograph after Trauma

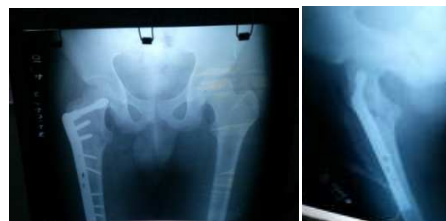

Fig 2: Immediate Post-Op

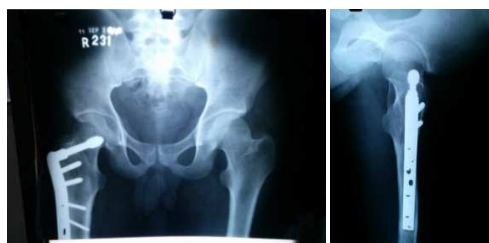

Fig 3: Follow-Up Radiographs

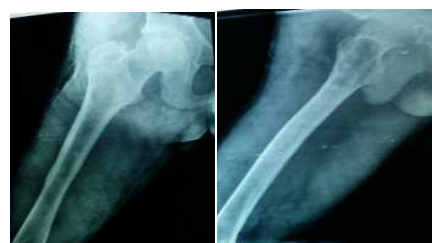

Fig 4: After Implant Removal

He developed insidious pain in the right hip which was dull aching, localized pain which increased on walking long distance and was relieved at rest. There was no history of any diurnal variation, any waxing or waning of symptoms, no history of any other trauma, no history of fever, no history of steroid, tobacco consumption or alcohol consumption. The pain increased in intensity and for the same he started pain medications which relieved the symptoms partially. He presented to us with pain on terminal motion of the right hip which affected his activities of daily living. On examination he had a surgical scar over the lateral aspect of the hip with tenderness over the right hip, the

Range of motion of the right hip were only terminally restricted with sectoral sign being positive. He was investigated in the form of standard radiographs and MRI which showed Grade 3 AVN. All other blood investigation was within normal limit. He was started on alendronate 70mg once a week and analgesics for the pain as the patient was unwilling for any surgical intervention and on the last follow up the patient was not on any analgesics and continuing the use of alendronate, the patient was pain free.

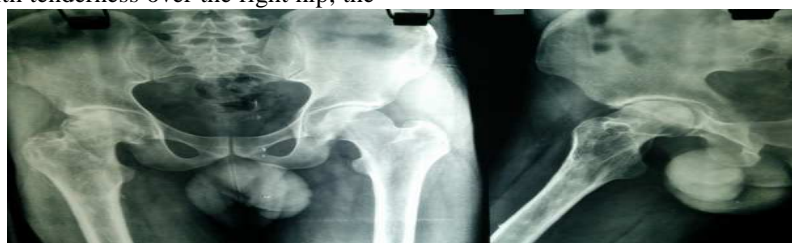

Fig 5: Presented to us with Right Hip pain




Fig 6: MRI showing grade 3 osteonecrosis



Fig 7: Follow-up Clinical Photos

Discussion

Unstable pertrochanteric fracture AO 31-A3 has been treated by various modalities. Possible fixation constructs include compression hip screws, intramedullary hip screws, trochanteric intramedullary nails, cephalomedullary antegrade intramedullary nails, and 95° plates. These have been associated with complications such as Implant failure, malunions, infection. Osteonecrosis of the femoral head following pertrochanteric femur fracture are a rare complication with the etiology of the osteonecrosis associated with trauma to the deep branch of medial circumflex femoral artery. Other possible causative factors are high energy trauma, fracture displacement, comminution at the fracture site. Osteonecrosis have been reported in 0.5- 1% of pertrochanteric fractures and predominantly in the older than 50 years of age. The review of literature states that the duration of developing osteonecrosis after stabilization of a pertrochanteric fracture have been 4 months to 4 years after stabilization. Osteonecrosis of femoral head is a rare but disabling condition that usually results in progressive femoral head collapse and secondary arthritis necessitating total hip arthroplasty if not treated appropriately in early stages. However, early diagnosis is challenging as the onset of disease is insidious and the symptoms and signs are usually minimal and nonspecific until it becomes advanced. Of

several diagnostic modalities, magnetic resonance imaging (MRI) is considered the imaging method of choice with the highest sensitivity and specificity, while detection of potential risk factors is very important as well. Symptomatic hip osteonecrosis is a disabling condition with a poorly understood aetiology and pathogenesis. Numerous treatment options for hip osteonecrosis are described, which include non-operative management and joint preserving procedures, as well as total hip replacement (THR). Non-operative or joint preserving treatment may improve outcomes when an early diagnosis is made before the lesion has become too large or there is radiographic evidence of femoral head collapse. The presence of a crescent sign, femoral head flattening, and acetabular involvement indicate a more advanced-stage disease in which joint preserving options are less effective than THR. A high suspicion of osteonecrosis of the femoral head in a patient with hip pain with operated pertrochanteric fractures will lead to early diagnosis and early treatment with non operative or joint preserving surgeries.

References

1. Avascular necrosis of the femoral head in pertrochanteric fractures: a report of 8 cases

- and a review of the literature. *J Orthop Trauma*. 2007 Apr; 21(4):229-36. Bartoníček J1, Fric V, Skála-Rosenbaum J, Dousa P.
2. Osteonecrosis of the femoral head: diagnosis and classification systems. *Curr Rev Musculoskelet Med*. 2015 Jun 19. [Epub ahead of print] Choi HR1, Steinberg ME, Y Cheng E.
 3. Agarwala S, Jain D, Joshi VR, Sule A. Efficacy of alendronate, a bisphosphonate, in the treatment of AVN of the hip: a prospective open-label study. *Rheumatology (Oxford)* 2005;44:352–359.
 4. Agarwala S, Shah SB. Ten-year follow-up of avascular necrosis of femoral head treated with alendronate for 3 years. *J Arthroplasty* 2011;26:1128–1134.
 5. Agarwala S, Shah S, Joshi VR. The use of alendronate in the treatment of avascular necrosis of the femoral head: follow-up to eight years. *J Bone Joint Surg Br* 2009;91-B:1013–1018.

Source of Support: Nil

Conflict of Interest: None